Arterien

- Aorta
  - Arcus aortae
  - Pars ascendens aortae
  - Pars descendens aortae
  - Pars thoracica aortae
  - Pars abdominalis aortae
  - Truncus coeliacus
- A. splenica
- A. hepatica communis
- Aa. gastricae
- A. mesenterica inferior
- A. mesenterica superior
- A. renalis
- A. iliaca communis
- A. iliaca externa
- A. iliaca interna
- A. carotis communis sinistra
- A. vertebralis
- Truncus brachiocephalicus
- A. subclavia
- A. carotis interna
- A. carotis externa
- A. thoracica interna
- A. axillaris
- A. brachialis
- A. ulnaris
- A. radialis
- A. femoralis
- A. poplitea
- A. tibialis posterior
- A. tibialis anterior
- A. fibularis

Venen

- V. jugularis externa
- V. jugularis interna
- Vv. pulmonales
- V. subclavia
- V. azygos
- V. hemiazygos
- V. axillaris
- V. cephalica
- V. basilica
- V. iliaca communis
- V. iliaca interna
- V. iliaca externa
- V. femoralis
- V. saphena magna
- V. brachiocephalica
- V. cava superior
- V. cava inferior
- Vv. hepaticae
- V. renalis
- V. portae hepatis
- Vv. gastricae
- V. splenica
- V. mesenterica inferior
- V. mesenterica superior
- V. poplitea

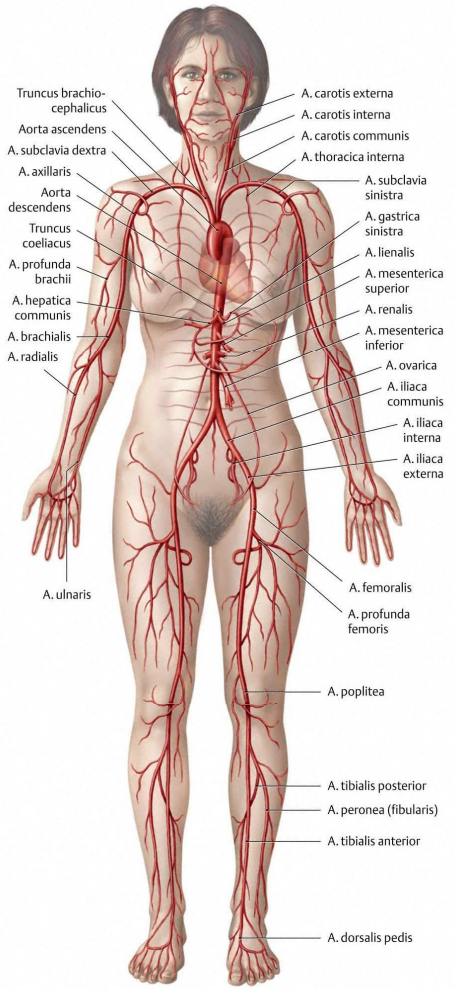

C Übersicht über die wichtigsten Arterien (Schlagadern) des Körperkreislaufes

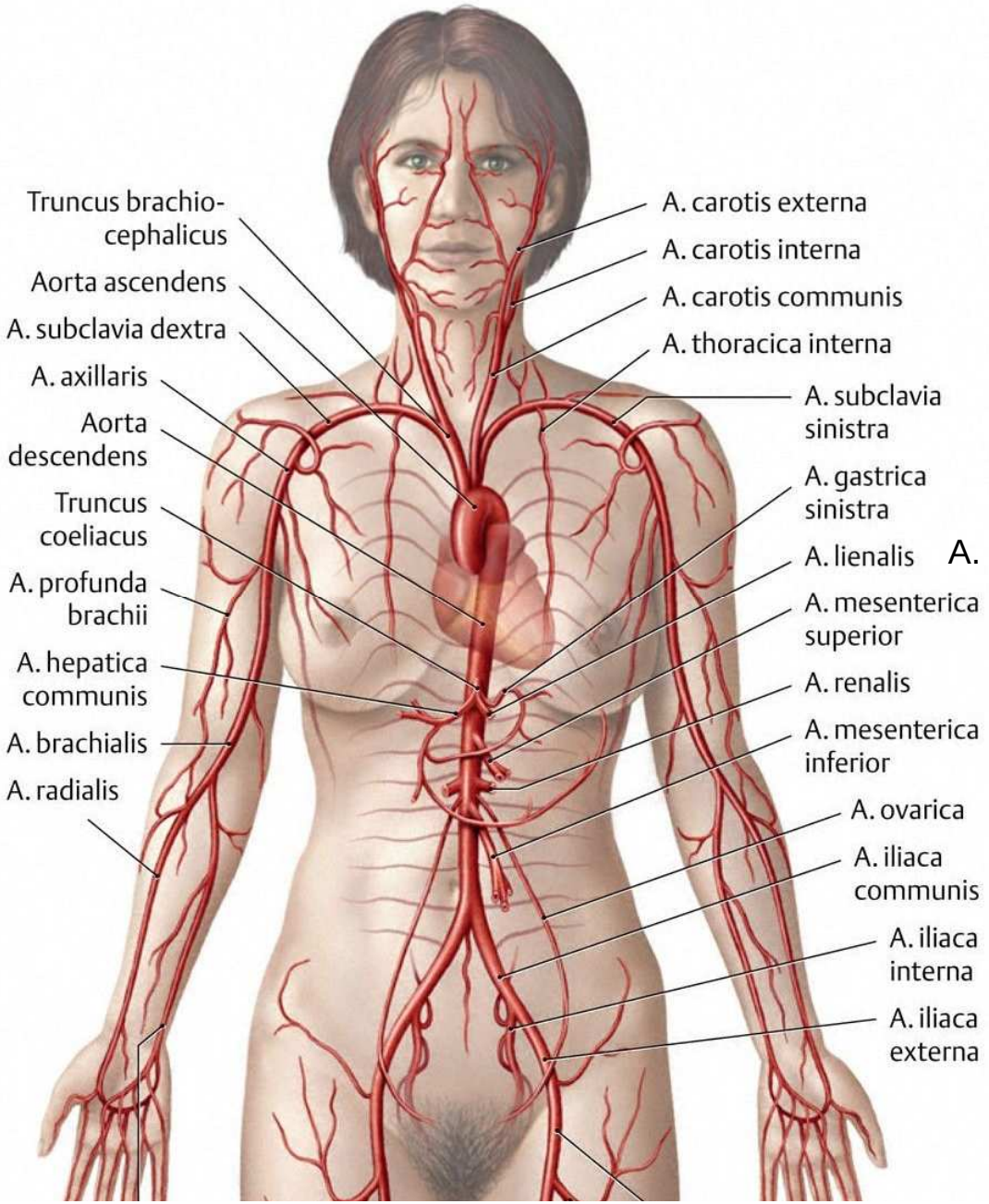

A. spleni

Medizintechnik

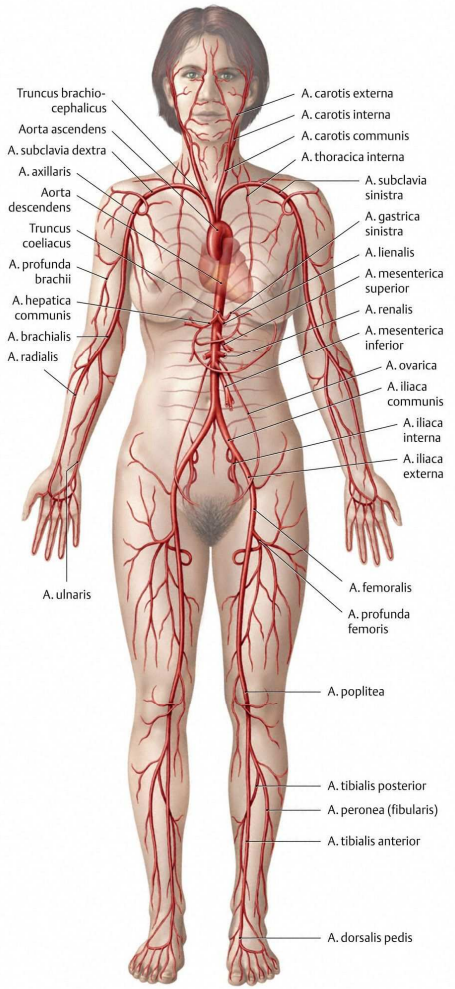

C Übersicht über die wichtigsten Arterien (Schlagadern) des Körperkreislaufes

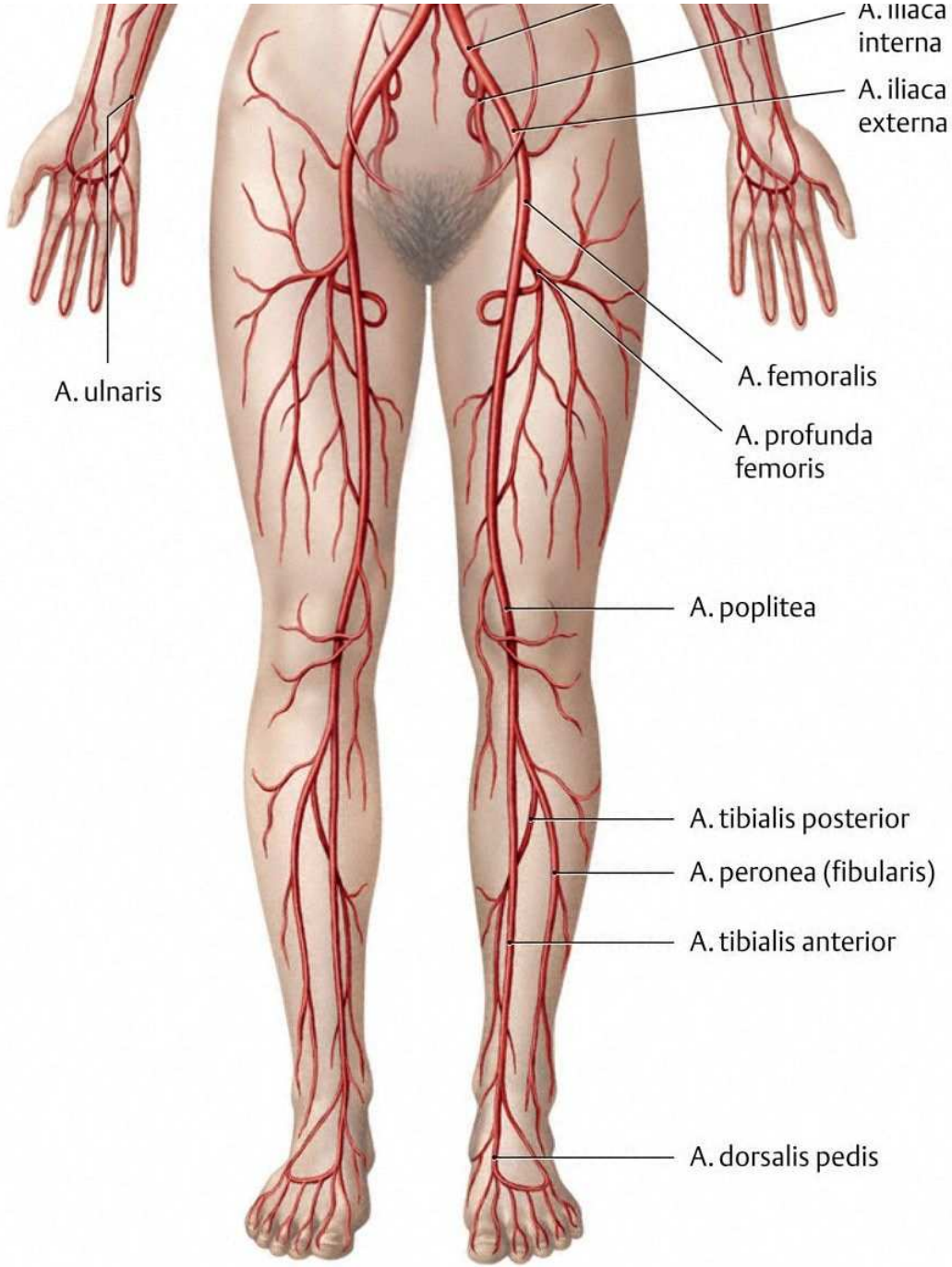

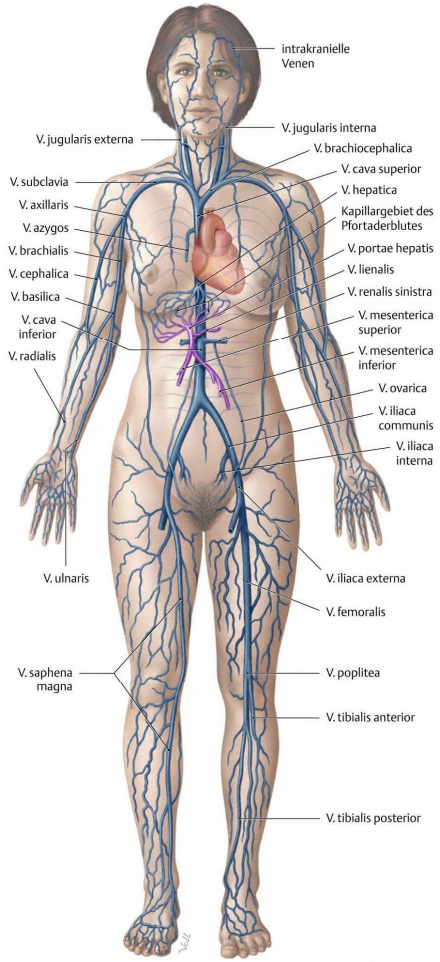

D Übersicht über die wichtigsten Venen (Blutadern) des Körperkreislaufes

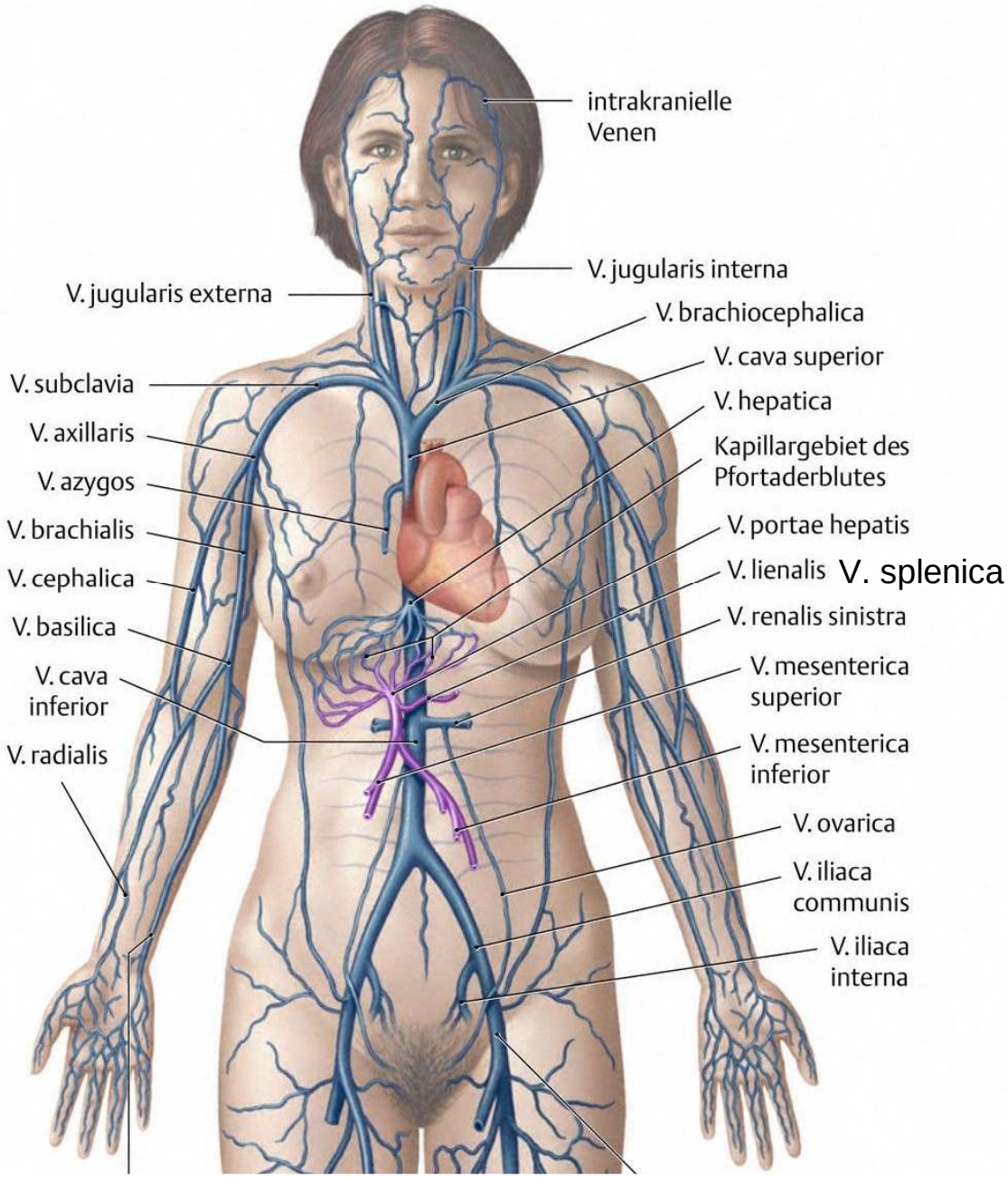

Medizintechnik

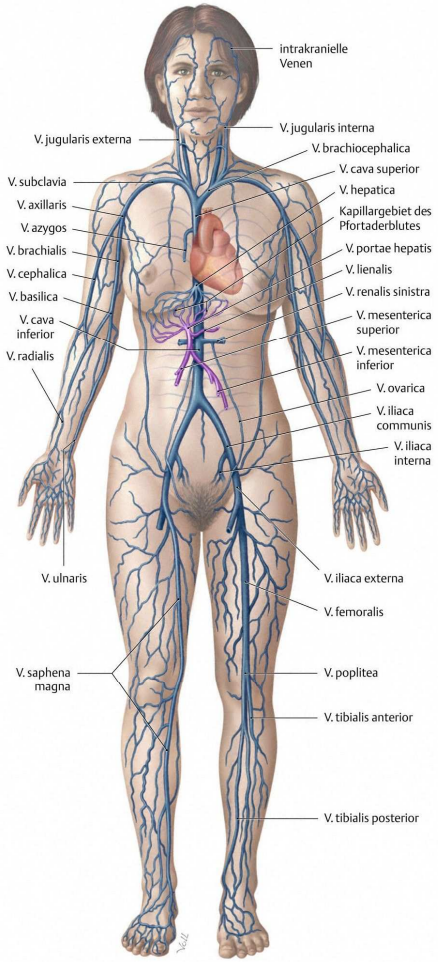

D Übersicht über die wichtigsten Venen (Blutadern) des Körperkreislaufes

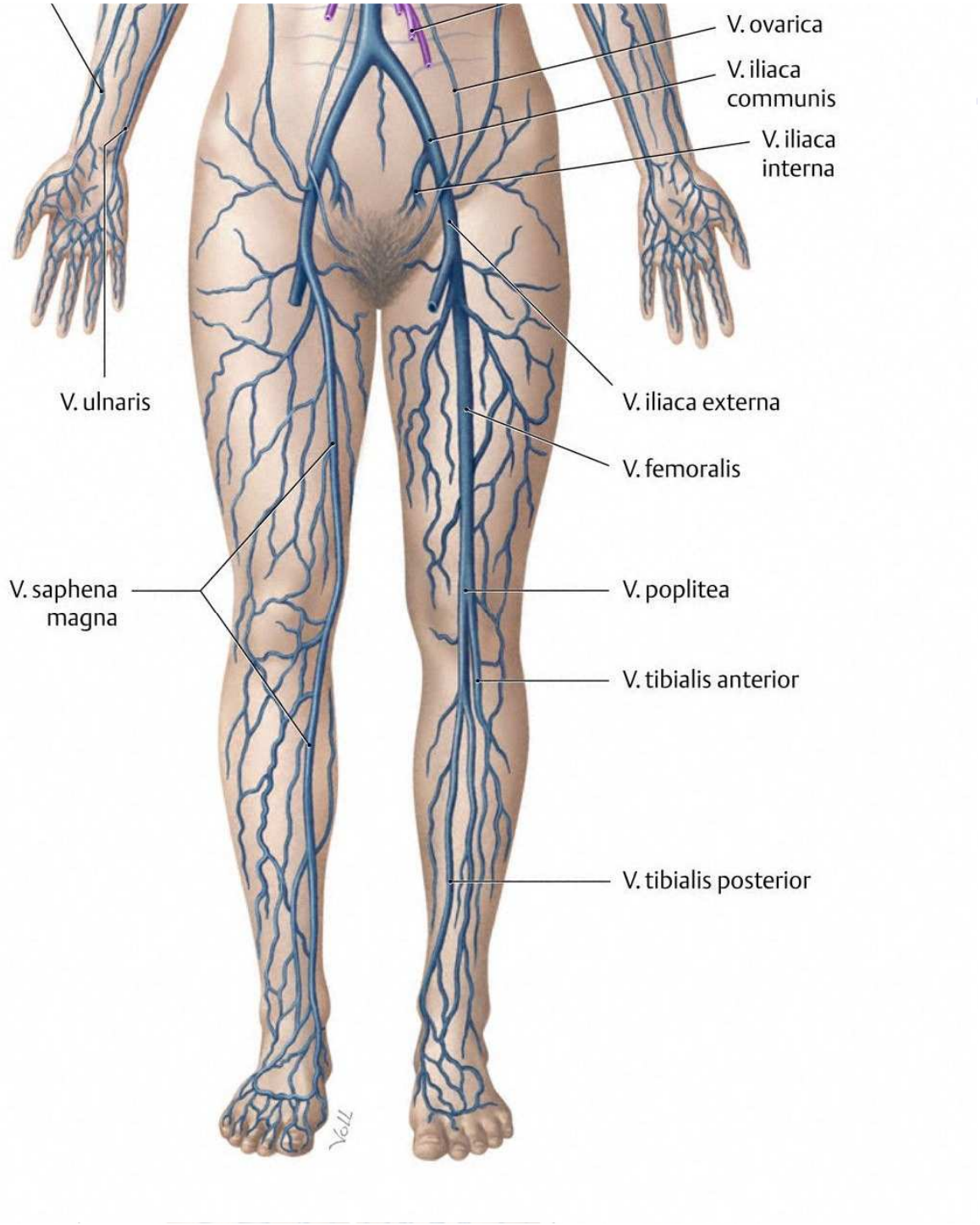

Vena portae hepatis (Pfortader)

